



AMERICAN SOCIETY OF CLINICAL ONCOLOGY

Clinical Practice Guideline: Optimum Imaging Strategies for Advanced Prostate Cancer is endorsed by the Society of Abdominal Radiology (SAR), American College of Radiology (ACR), Society of Nuclear Medicine and Molecular Imaging (SNMMI), American Urological Association (AUA), American Society for Radiation Oncology (ASTRO), and Society of Urologic Oncology (SUO).

Optimum Imaging Strategies for Advanced Prostate Cancer

Adapted from:

Trabulsi EJ et al. *J Clin Oncol*. 2020 Jan 15
doi: 10.1200/JCO.19.02757

Introduction

Treatment

↪ Introduction

- **Prostate cancer is the most common non-dermatologic cancer in men. In 2019, it was estimated that there would be 174,650 new cases in the United States, and in spite of advances in diagnosis and treatment, an estimated 31,620 deaths would occur.**
- **Prostate cancer poses unique challenges:**
 - A distinct clinical disease state characterized by an elevated serum prostate specific antigen (PSA) consistent with recurrent disease without findings of metastases on historically conventional imaging studies
 - Difficulty in monitoring patients with metastatic bone disease due to the poor test characteristics of conventional bone imaging
 - Increasing evidence for
 - ▶ Local salvage therapy
 - ▶ Metastasis-directed therapy
 - ▶ Increasingly effective early systemic therapies
- **The predilection for prostate cancer to metastasize to bone and lymph nodes requires both bone and soft tissue imaging techniques.**
- **Advances in nuclear medicine and molecular imaging are poised to reinvent the way in which we diagnose, stage and monitor response to therapy in patients with prostate cancer.**

↪ Treatment

- **Recommendation 1. Imaging is recommended for all patients with advanced prostate cancer. (See Recommendations 4.1-11 for specific details according to clinical scenario) (Strong Recommendation; EB-B-I).**
- **Recommendation 2. One or more of the following imaging modalities should be used for patients with advanced prostate cancer: conventional imaging (defined as computed tomography, bone scan and/or prostate MRI), and/or next generation imaging (NGI) (PET, PET/CT, PET/MRI, whole body MRI), according to clinical scenario (Strong Recommendation; EB-B-I).**
- **Recommendation 3. It is recommended when choosing an imaging modality that disease states and clinical scenarios as described are taken into consideration, since the imaging modality may guide treatment or change clinical treatment decisions (Strong Recommendation; EB-B-I).**

Newly Diagnosed Clinically High-Risk/Very High-Risk Localized Prostate Cancer

Conventional imaging negative

- Recommendation 4.1. When conventional imaging is negative, next generation imaging may be offered to patients for potential detection of sites of disease amenable for treatment, although prospective data are limited. (Moderate Recommendation; IC-U-W).

Conventional imaging suspicious/equivocal

- Recommendation 4.2. When conventional imaging is suspicious or equivocal, NGI may be offered to patients for clarification of equivocal findings or detection of additional sites of disease which could potentially alter management, although prospective data are limited. (Moderate Recommendation; IC-U-L).

Rising PSA after prostatectomy and negative conventional imaging (either initial PSA undetectable with subsequent rise or PSA never nadirs to undetectable)

- Recommendation 4.3. For men that are not candidates or are unwilling to receive salvage local or regional therapy, additional NGI should not be offered. (Moderate Recommendation; IC-U-L).
- Recommendation 4.4. For men for whom salvage radiotherapy is contemplated, NGI should be offered (PSMA imaging (where available), C-11 choline or F-18 fluciclovine PET/CT or PET/MRI, whole body MRI and/or F-18 NaF PET/CT) since they have superior disease detection performance characteristics and may alter patient management (Strong Recommendation; EB-B-H).

Rising PSA after radiotherapy and negative conventional imaging

- Recommendation 4.5. For men in whom salvage local or regional therapy is not planned or is inappropriate, there is little evidence that NGI will alter treatment or prognosis. The role of NGI in this scenario is unclear and should not be offered, except in the context of an IRB (Institutional Review Board) approved clinical trial. (Moderate Recommendation; IC-U-I).

▶ Treatment

-
- ▶ **Recommendation 4.6.** For men for whom salvage local or regional therapy (e.g., salvage prostatectomy, salvage ablative therapy, or salvage lymphadenectomy) is contemplated, there is evidence supporting NGI for detection of local and/or distant sites of disease. Findings on NGI could guide management in this setting (e.g., salvage local, systemic or targeted treatment of metastatic disease, combined local and metastatic therapy). PSMA imaging (where available), C-11 choline or F-18 fluciclovine PET/CT or PET/MRI, whole body MRI and/or F-18 NaF PET/CT have superior disease detection performance characteristics compared to conventional imaging and alter patient management, although data are limited (**Moderate Recommendation; EB-B-I**).

Metastatic prostate cancer at initial diagnosis or after initial treatment, hormone sensitive

- ▶ **Recommendation 4.7.** In the initial evaluation of men presenting with hormone-sensitive disease with demonstrable metastatic disease on conventional imaging, there is a potential role for NGI to clarify the burden of disease and potentially shift the treatment intent from multimodality management of oligometastatic disease to systemic anti-cancer therapy alone or in combination with targeted therapy for palliative purposes, but prospective data are limited (**Moderate Recommendation; IC-U-I**).

Non-metastatic CRPC (nmCRCP)

- ▶ **Recommendation 4.8.** For men with nmCRPC, NGI can be offered only if a change in the clinical care is contemplated. Assuming patients have received or are ineligible for local salvage treatment options, NGI may clarify the presence or absence of metastatic disease, but the data on detection capabilities of NGI in this setting and impact on management are limited (**Moderate Recommendation; IC-U-L**).

Metastatic CRPC

PSA progression

- **Recommendation 4.9.** PSA progression alone for men on treatment for metastatic CRPC should not be the sole reason to change therapy. Conventional imaging can be utilized for initial evaluation of PSA progression and should be continued to facilitate changes/comparisons and serially to assess for development of radiographic progression. (**Strong Recommendation; IC-U-I**).
- **Recommendation 4.10.** The use of NGI in this cohort is unclear, with a paucity of prospective data. When a change in clinical care is contemplated, in an individualized manner, and there is a high clinical suspicion of subclinical metastasis despite negative conventional imaging, the use of NGI could be contemplated, especially in the setting of a clinical trial (**Weak Recommendation; IC-U-Ins**).

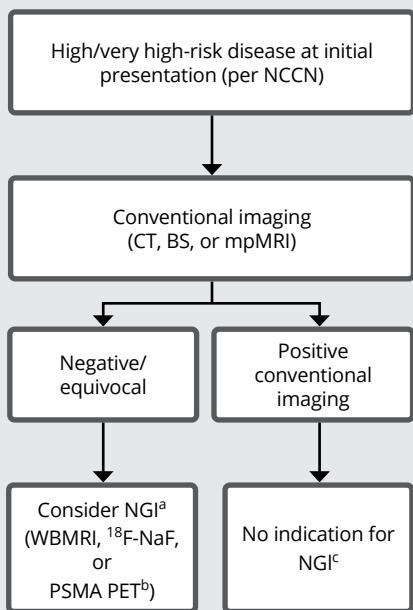
Radiographic progression on conventional imaging

- **Recommendation 4.11.** In men with metastatic CRPC with clear evidence of radiographic progression on conventional imaging while on systemic therapy, NGI should not be routinely offered. NGI may play a role if performed at baseline to facilitate comparison of imaging findings/extent of progression of disease (**Moderate Recommendation; IC-U-Ins**).

Abbreviations

BS, bone scintigraphy; CRPC, castration-resistant prostate cancer; CT, computerized tomography; Mets, metastatic disease; mpMRI, multiparametric magnetic resonance imaging; MRI, magnetic resonance imaging; NCCN, National Comprehensive Cancer Network; NGI; next generation imaging; PET, positron emission tomography; PSA, prostate specific antigen; PSMA, prostate specific membrane antigen; WB, whole body

Figure 1. Imaging Algorithm for High/Very High-Risk Disease at Initial Presentation (per National Comprehensive Cancer Network [NCCN])

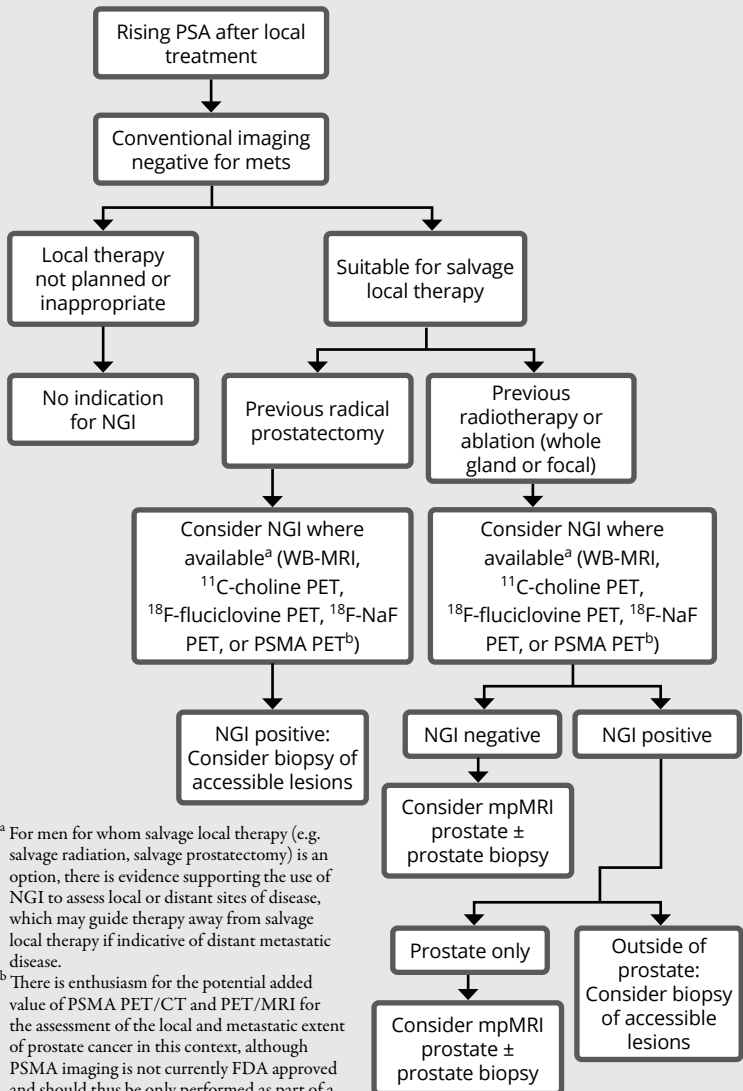


^a Suspicious findings on NGI would influence treatment decisions in patients with advanced prostate cancer and negative conventional imaging, opening the scope for multimodality treatment of primary and oligometastatic disease or systemic therapy for more extensive metastatic states, although prospective data are limited.

^b There is enthusiasm for the potential added value of PSMA PET/CT and PET/MRI for the assessment of the local and metastatic extent of prostate cancer in this context, although PSMA imaging is not currently FDA approved and should thus be only performed as part of a clinical trial or other controlled research setting.

^c NGI could offer clinical benefit in this scenario by redefining the true extent of disease and shifting treatment decisions accordingly, although prospective data in this context are limited.

Figure 2. Imaging Algorithm for Patients with Rising Prostate-Specific Antigen (PSA) After Local Treatment



^a For men for whom salvage local therapy (e.g. salvage radiation, salvage prostatectomy) is an option, there is evidence supporting the use of NGI to assess local or distant sites of disease, which may guide therapy away from salvage local therapy if indicative of distant metastatic disease.

^b There is enthusiasm for the potential added value of PSMA PET/CT and PET/MRI for the assessment of the local and metastatic extent of prostate cancer in this context, although PSMA imaging is not currently FDA approved and should thus be only performed as part of a clinical trial or other controlled research setting.

Recommendation Grading

Type		Benefit/harm		Evidence Quality		Strength of Recommendation
EB	Evidence-based	B	Benefits outweigh harms	H	High	Strong
CB	Consensus-based	H	Harms outweigh benefits	I	Intermediate	Moderate
IC	Informal consensus	B/H	Relative balance of benefits and harms	L	Low	Weak
		U	Unknown	Ins	Insufficient	

ASCO believes that cancer clinical trials are vital to inform medical decisions and improve cancer care and that all patients should have the opportunity to participate.

Additional information, which may include data supplements, slide sets, and other clinical tools and resources, is available at www.asco.org/genitourinary-cancer-guidelines.



The printing and distribution of this education resource is sponsored and provided by Blue Earth Diagnostics, Inc. It is intended for reference use only and healthcare providers must make clinical judgments based on their independent assessment of each patient. Blue Earth Diagnostics, Inc. was not involved in the development of the publication or the underlying guidelines on which this publication is based.

Source

Trabulsi EJ et al. Optimum Imaging Strategies for Advanced Prostate Cancer: ASCO Guideline. *J Clin Oncol*. 2020 Jan 15 doi: 10.1200/JCO.19.02757.

Disclaimer

This pocket guide is derived from recommendations in the American Society of Clinical Oncology Guideline. This resource is a practice tool based on ASCO® practice guidelines and is not intended to substitute for the independent professional judgment of the treating physician. Practice guidelines do not account for individual variation among patients. This pocket guide does not purport to suggest any particular course of medical treatment. Use of the practice guidelines and this resource are voluntary. The practice guidelines and additional information are available at www.asco.org/genitourinary-cancer-guidelines. Copyright © 2020 by American Society of Clinical Oncology. All rights reserved.



International
Guidelines
Center

ASCOOPT2012a_br

106 Commerce Street, Suite 105
Lake Mary, FL 32746
TEL: 407.878.7606 • FAX: 407.878.7611
Order additional copies at GuidelineCentral.com
Copyright © 2020 All rights reserved

